

# Hip resurfacing with a highly cross-linked polyethylene acetabular liner and a titanium nitride-coated femoral component

HIP International  
1–7  
© The Author(s) 2018  
Reprints and permissions:  
sagepub.co.uk/journalsPermissions.nav  
DOI: 10.1177/1120700017752334  
journals.sagepub.com/home/hpi  


James W Pritchett

## Abstract

**Aims:** This study evaluated a specific hip resurfacing system to determine the: (1) function and complications, (2) implant survivorship, (3) acetabular bone conservation and joint biomechanics and (4) osteolysis and polyethylene wear.

**Methods:** I performed 234 resurfacing procedures (192 patients) using a two-piece titanium acetabular component with a 4 mm highly cross-linked polyethylene liner and a cementless titanium nitride-coated titanium femoral component. Function was assessed with Harris Hip, WOMAC, SF-12, and UCLA scores. Radiography and CT scans were used to evaluate bone retention, component position, joint biomechanics, and osteolysis. Retrieved polyethylene liners were analyzed for wear.

**Results:** Median follow-up was 8 years and patients averaged 48 years of age at surgery. The mean Harris Hip Score was 96 and all scores improved significantly. Kaplan-Meier survivorship was 97%. The mean medial acetabular thickness was 9 mm postoperatively versus 14 mm preoperatively ( $p = 0.019$ ). Femoral bone conservation (head:neck ratio) was 1.36 postoperatively versus 1.42 preoperatively ( $p = 0.02$ ). There was no polyethylene wear through or osteolysis. Eight polyethylene retrievals had a mean wear of 0.05 mm/yr.

**Conclusions:** Resurfacing with a highly cross-linked polyethylene acetabular component and a titanium nitride-coated titanium cementless femoral component is a reliable and bone-conserving procedure at mid-term.

## Keywords

Highly cross-linked polyethylene, hip resurfacing, titanium femoral component

Date received: 31 December 2017; revised: 5 July 2017; accepted: 4 September 2017

## Introduction

Hip resurfacing preserves femoral bone but the procedure has been limited by technical difficulty, health of the preserved bone, and wear and fixation of the bearing surfaces.<sup>1–5</sup> Resurfacing patients have a lower incidence of mortality at 10 years compared to patients undergoing total hip replacement (THR).<sup>6,7</sup> Resurfacing has procedural advantages such as an easier femoral revision when necessary, smaller volume of implanted material, and ability to offer the procedure when the medullary canal is blocked. The functional advantages of resurfacing over THR are enhanced stability and greater possibility for patients to participate in sports and other activities.<sup>1,8–10</sup>

There is no universal agreement about these benefits of hip resurfacing, possibly due to previous problems with

the procedure.<sup>11,12</sup> Metal-on-polyethylene resurfacing was unsuccessful because the thin conventional polyethylene was vulnerable to wear and the thick cementless metal-backed or cemented fixation was intrusive to the pelvis, resulting in failures that were sometimes difficult to reconstruct.<sup>3–5,13,14</sup> The most recent metal-on-metal (MoM) resurfacing components are very thin.<sup>1,9,15,16</sup> However,

---

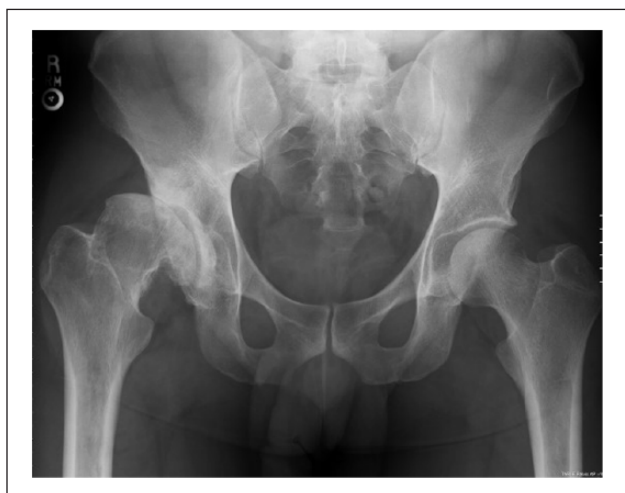Wyss Hip and Pelvis Center, Seattle, USA

### Corresponding author:

James W Pritchett, Wyss Hip and Pelvis Center, 901 Boren Ave #900, Seattle, WA 98104, USA.  
Email: bonerecon@aol.com



**Figure 1.** The resurfacing implants used were two-piece acetabular components, consisting of a porous titanium shell and an XLPE liner. The femoral component is TiN-coated titanium.



**Figure 2a.** This anteroposterior (AP) pelvis radiograph shows a 33-year-old man with severe right hip osteoarthritis and dysplasia.

there have been some instances of serious tissue damage due adverse reactions to metal wear debris, particularly in small-size components.<sup>15–18</sup> The more wear-resistant highly cross-linked polyethylenes (XLPE) that have benefitted THR can now be applied to resurfacing.<sup>19–21</sup> Highly cross-linked polyethylene acetabular liners can be made in dimensions suitable for resurfacing.<sup>22,26–28</sup>

This study evaluated a cementless hip resurfacing system comprised of a two-piece acetabular component consisting of a 2-mm titanium shell with 1 mm of porous coating and a bearing surface of XLPE. Both femoral and acetabular components have a 10  $\mu$  coating of titanium nitride (TiN) over the titanium substrate (Figure 1). Cobalt-chromium implants have been used by the author<sup>29</sup> and others in prior published work. This study sought to determine

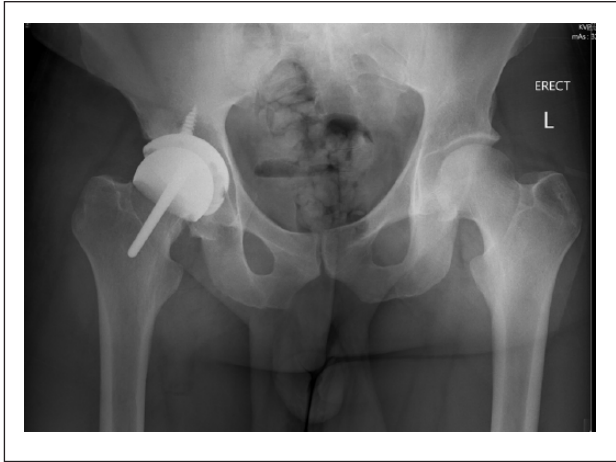the: (1) functional outcome and complications, (2) implant survivorship, (3) bone conservation and biomechanics, and (4) incidence of osteolysis and polyethylene wear.

## Methods

The Institutional Review Board approved this single-center prospective study **conducted between January 2006 and January 2011**. There were 192 participants (234 hip procedures). A single surgeon with many years of experience with polyethylene hip resurfacing performed all the procedures. All patients who met all of the following inclusion criteria were offered enrollment in the study: (1) pain and functional compromise that made a patient a candidate for THR, (2) femoral head diameter of 41–51 mm, (3) UCLA score goal of six or higher, (4) age  $\leq$  65 years, and (5) satisfactory bone quality and geometry (Figure 2a), defined as bone structure that could accommodate the resurfacing components without notching the femoral cortex or over-reaming the acetabulum (medial wall thickness  $>5$  mm). Enrollment was not affected by the presence of abnormalities in the hip center of rotation, femoral offset, or the shape of the femoral head or neck.

The option of THR was discussed with all patients but those included in this study chose hip resurfacing. Exclusion criteria were: (1) poor femoral bone quality as indicated by femoral head cysts or osteonecrosis defects  $>2$  cm, (2) below normal bone density determined by plain radiograph, and (3) geometry that would not allow stable placement of the acetabular prosthesis with at least 5 mm of medial acetabular wall preservation and a postoperative femoral head:neck ratio of at least 1.29 without notching. Bone quality was assessed qualitatively as within or below the normal range.<sup>2,10</sup> We did not use DEXA or MRI scans to determine candidacy for hip resurfacing.

All femoral prostheses were porous-coated and stemmed (New Jersey Conservative Femoral Resurfacing, FDA 510 K904870) and all were placed without cement. The two-piece acetabular components consisted of a porous-coated titanium shell from 52 mm to 64 mm with a 41–51 mm XLPE liner (BP Hemispherical Acetabular Cup, FDA 510 K963101) (Figure 1). The acetabular shells are placed without cement and screw fixation is possible if the shell is supported incompletely by the underlying acetabular dysplasia. A secure, threaded, central impactor allows full visualization of the shell during impaction and contact of the acetabular shell with the bone can be verified easily through the impactor hole in the shell. The polyethylene liners were fabricated from GUR 1020 resin (Ticona, Kelsterbach, Germany) highly cross-linked by exposure to gamma irradiation at 7.5 Mrads followed by heating to 155°C, which is above the polyethylene melting temperature, and then sterilized with Ethylene Oxide (Mediatech, Fort Wayne, IN, USA). The polyethylene thickness was 4 mm.



**Figure 2b.** The postoperative radiograph shows the resurfaced hip, using a two-piece acetabular component with an XLPE component and a cementless porous coated TiN-coated titanium femoral component.

Each femoral component fits with a specific matching (300  $\mu\text{m}$  radial clearance) acetabular bearing and each acetabular bearing fits a specific acetabular shell. The acetabular component is designed to be placed at 30–45° of inclination and from 0° to 25° of anteversion. The goal for combined femoral and acetabular anteversion is a maximum of 45°. The femoral stem was placed from neutral to 15° of valgus relative to the native femoral neck. The thin flexible acetabular shell is placed with under-reaming of the acetabular bone. Typically, the components can be placed with a 9 mm or 10 mm differential between the acetabular and femoral preparation compared to 6 mm with MoM.<sup>1,9</sup> The shell, XLPE, and locking mechanism are tolerant of deformation allowing better acetabular bone preservation. This assembly provides a several-millimeter benefit in acetabular bone conservation over predicate polyethylene implants.<sup>4,5,13,14,26–28</sup>

Participants had no limitations following their initial recovery and were permitted immediate weight bearing. The UCLA Activity Score was used preoperatively to identify each patient's postoperative goals. Follow-up examinations were performed at 8 weeks, 6 months, and annually, and outcomes were assessed using the Modified Harris Hip Score, WOMAC instrument, the 12-item Short Form Health Survey (SF-12), and UCLA Hip Score.<sup>1,30–32</sup> Follow-up evaluation also included a digital anteroposterior (AP) view radiograph of the pelvis centered over the symphysis (Figure 2b), an AP view of the hip centered over the femoral head, and a Johnson shoot-through lateral radiograph.<sup>33</sup> All but two patients who died and two who were lost to follow-up were seen in the clinic.

Two **blinded** independent observers not involved in this study analyzed the radiographs. Cup inclination and anteversion angles were measured on the pelvic and Johnson radiographs and CT scans. Femoral component

inclination was also measured with respect to the preoperative femoral neck shaft angle. The radiographs were evaluated for radiolucent lines and osteolysis in the acetabular zones as described by DeLee and Charnley<sup>34</sup> and fixation of the femoral component was evaluated radiographically as described by Amstutz, et al.<sup>1</sup> The acetabular components were inspected radiographically for signs of osseointegration. The presence of spot welds and bone trabeculae through the metal indicated ingrowth; radiolucencies or migration indicated failure of ingrowth. All radiographs were examined for osteolysis, which was defined as an area of lucency seen within bone with a defined border sclerotic border. Lucent areas were compared to preoperative films.<sup>35</sup>

High-resolution CT scans with a Sensation 16 scanner (Siemens Medical Solutions, Forchheim, Germany) with metal-artifact reduction software were performed in 51 participants when they presented 6–11 years postoperatively. Qualitative polyethylene wear and related osteolysis were assessed by CT scan but precise radiographic and CT scan measurement of polyethylene wear is beyond the scope of this study and will be addressed in future studies. In addition to digital radiographs, CT scans were used to assess biomechanics and bone conservation. Femoral bone conservation was measured using the head:neck ratio and acetabular bone conservation was measured by the medial acetabular wall thickness as the shortest distance from the cup and the pelvic brim. Measurements also included the distance to Kohler's line, the horizontal center of rotation to assess hip biomechanics and acetabular bone retention, limb length (the perpendicular distance from the horizontal teardrop to the base of the lesser trochanter), the vertical center of rotation, and horizontal femoral head offset.<sup>10,36</sup> When calculating biomechanics, the resurfaced hip was compared to the normal contralateral hip (if present) and to the preoperative hip.

Explanted liners were inspected using optical microscopy for evidence of rim damage, cracking, and fatigue. The rim was inspected and scored as a single entity, specifically looking for abrasion, burnishing, scratching, embedded debris, and plastic deformation.<sup>19,20,37</sup> The liners were used to calculate polyethylene wear. Linear femoral head penetration was measured with a digital coordinate measuring machine (Mitutoyo America Corporation, Aurora, IL, USA). The polyethylene thickness in 300 points was measured in loaded and unloaded areas. We calculated the mean femoral head penetration rate by dividing the measured head penetration by time (mm/yr.).

### Statistical analysis

Two-tailed, paired, Student *t* tests were used to compare the postoperative and most recent follow-up clinical scores. A *p* value < .05 was deemed significant. We used Kaplan-Meier survivorship method with revision for any

**Table 1.** Patient demographics and preoperative data.

Patients <i>n</i> = 192 Procedures <i>n</i> = 234	Women <i>n</i> = 98	Men <i>n</i> = 94
Age (mean years)	49	47
Range	24–67	23–68
BMI (mean, kg/M <sup>2</sup> , range)	25 (19–38)	29 (24–41)
<b>Preoperative Diagnoses</b>		
Osteoarthritis = 125	63	62
Prior trauma surgery = 22	9	13
Degeneration from dysplasia, Perthes disease, slipped epiphysis, other developmental disorders = 87	46	41

**Table 2.** Results of scoring assessments.

Instrument	Preoperative mean (range)	Postoperative mean (range)	<i>p</i> value
Harris Hip	51 (21–81)	96 (52–100)	<0.0001
WOMAC	52 (30–68)	5 (0–16)	<0.0001
SF-12			
Mental	46 (22–61)	54 (24–64)	<0.005
Physical	36 (22–48)	54 (26–64)	<0.0001
UCLA	4 (2–7)	8 (6–10)	<0.0001

reason as the endpoint. The statistical software was SPSS v. 19 (SPSS, Chicago, IL).

## Results

The follow-up period ranged from 6 years to 11 years (median, 8 years). Two participants were lost to follow-up and two died from unrelated causes. **Patient demographics are shown in Table 1.**

Participants' mean preoperative UCLA Activity Score goal for activity was eight (range, 6–10), defined as very active.<sup>1</sup> The postoperative functional results as assessed by the Harris Hip Score, WOMAC, SF-12, and UCLA activity scores all improved significantly (Table 2). Eighty percentage of the patients achieved a postoperative UCLA score of 8 or greater. The average acetabular component inclination was 41° (range 30–53°) and the average anteversion was 15° (range, 0–25°). The average femoral anteversion was 13° (range, 0–20°). All femoral components were neutral or placed in a valgus orientation with respect to the native femur. Screw fixation was used in 9% of patients when the shell was ≥20% uncovered (Figure 2b).

There were complications that did not interfere with the outcome (three wound infections and two cases of Brooker two heterotopic ossification).<sup>30</sup> There were no dislocations. Four patients continued to report pain (two mild, one moderate, one significant). There were no instances of osteolysis identified by either radiograph or CT scan. Radiolucent lesions were seen in eight hips but

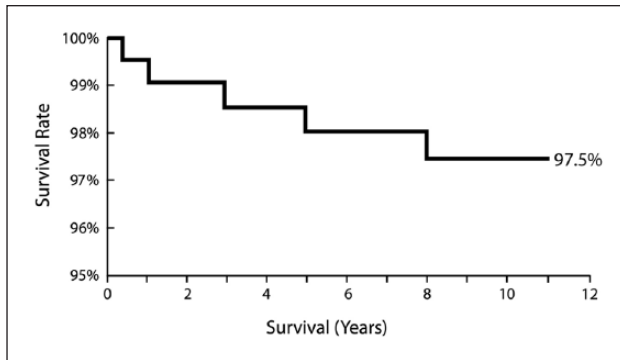
comparison to preoperative radiographs showed that these were cystic lesions of the acetabulum.

Five patients (2%) underwent successful revision of their femoral component from 3 years to 11 years following the initial surgery. The causes of failure were femoral neck fracture (*n* = 2), femoral loosening or subsidence (*n* = 2), and infection (*n* = 1). In all five revisions, the metal-backed acetabular component was preserved and the acetabular liner was exchanged to allow use of new XLPE. There was one acetabular revision for loosening. A new shell with screw fixation resulted in a secure component and successful outcome. Using revision for any reason as the endpoint, the Kaplan-Meier survival estimate of mean survivorship was 97.5% (95% confidence interval, 95–98.9%) at 10 years (Figure 3). There were no bearing-surface failures or pending revisions.

Eight polyethylene retrieval specimens obtained at revision or post-mortem at periods of 3, 5, 7, 8, 9, 9, 10, and 11 years post-resurfacing showed a mean wear rate of 0.05 mm/yr. (range; 0.03–0.07 mm/yr.). There was no internal or rim cracking, scratching, burnishing, or delamination, and the original machining marks were visible on seven of the eight liners. Two liners showed signs of polyethylene creep into the screw holes.

Seventy-six patients had a normal contralateral hip, 42 had a contralateral hip resurfacing, 9 had a contralateral THR, 43 had a dysplastic contralateral hip, and 22 had an osteoarthritic contralateral hip. Among the nine patients with a contralateral THR, the same size acetabular component was used in five, a smaller size in one, and a 1 mm or 2 mm larger size in three. Postoperatively, the mean acetabular wall thickness was 9 mm versus 14 mm preoperatively and the head:neck ratio was 1.36 versus 142. The mean postoperative/preoperative horizontal center of rotation was 33/40 mm and the vertical center of rotation was 16/17 mm. When compared to the normal contralateral hip, the mean horizontal center of rotation was 4 mm medialized, the vertical center of rotation was 2 mm lower, the horizontal femoral offset was 1 mm medialized. The mean postoperative leg length increased 4 mm compared to preoperative length. The mean distance from the acetabular component to Kohler's line was 3.6 mm (range, 1.0–4.7 mm).





**Figure 3.** This is the Kaplan-Meier survivorship curve for XLPE TiN-coated hip resurfacing.

Two patients required more reaming than planned to achieve a stable prosthesis. No patient had compromise of the medial wall or femoral neck.

## Discussion

Because of the appeal of preserving bone and the stability of the natural-sized femoral head, there remains an interest in hip resurfacing. Prior resurfacing efforts with conventional polyethylene failed from impingement, wear, and osteolysis of the large diameter, thin acetabular components.

This study evaluated a specific cementless XLPE hip resurfacing system and found satisfactory functional results, bone conservation, maintenance of biomechanics, and implant survivorship. A specific difference in this report to my previous study<sup>29</sup> is the use of a titanium rather than cobalt-chromium femoral prosthesis and remelted rather than triple-annealed polyethylene. Also, femoral sizes up to 51 mm were included rather than only 40 mm and 44 mm. There was no osteolysis and no polyethylene liners failed. There was one instance of acetabular loosening and two instances of femoral loosening. Femoral neck fracture occurred twice, deep infection occurred once, resulting in six revisions (2.5%). The survivorship and wear results in this series using XLPE are far superior to outcomes using the same implant with conventional polyethylene.<sup>3,38,39</sup> In addition, participants made statistically significant functional gains in all measured parameters and achieved their stated preoperative goals, which were very high.

Limitations of this study include its mid-term follow-up, yet this is comparable to the follow-up periods of most other hip resurfacing reports.<sup>1,9,15,16,40</sup> A single surgeon with extensive experience, particularly in polyethylene hip resurfacing, performed all procedures, thus, these results may not be reproducible in other centers. The specific value of TiN coating and cementless femoral fixation was not evaluated in this study and would need a separate evaluation.

The mean polyethylene wear of 0.05 mm/yr. is consistent with other studies and no patient had wear greater than the osteolysis threshold of 0.1 mm/yr.<sup>41</sup> The performance of the polyethylene in this study is consistent with previous published THR studies using XLPE.<sup>20,23,37</sup> There are clinical and wear simulator studies with XLPE liners showing very low wear for 3–3.8 mm in thickness and 40–46 mm in inner dimension.<sup>19–22,24,37</sup> I recently published a wear simulator study that tested the largest polyurethane and XLPE liners available compared to conventional polyethylene and polyurethane.<sup>21</sup> Testing was conducted on 4-mm-thick, 51-mm-capacity acetabular implants using a biaxial hip simulator for 30 million cycles. The XLPE was more wear resistant than polyurethane and conventional polyethylene. The satisfactory results of this study show that XLPE acetabular liners should provide more than 20 years of expected use in active patients and support its continued use in hip resurfacing.

The bone conservation and biomechanics afforded by polyethylene hip resurfacing can be compared to both THR and MoM hip resurfacing. Studies have compared bone retention of MoM resurfacing to THR. There is typically 2 mm of acetabular component medialization with resurfacing compared to THR.<sup>42,43</sup>

The acetabular shell in this study has been used since 1989<sup>38,39</sup> It is very similar to the Townley and Indiana Conservative prostheses that date back to the 1970s.<sup>4,5,14</sup> It successfully challenged the engineering limits known for fracture and deformation of thin two-piece shells. Also, an effective locking mechanism has not been available for thinner acetabular components. Thinner components would need to be one-piece. One-piece components will have the attendant difficulties of providing an effective insertion tool and method for later bearing surface exchange if necessary, as well as limiting the possibility for adjunctive screw fixation.

There are a few prior reports about using XLPE for resurfacing applications and the present study will continue to acquire additional and longer term data.<sup>2,26,29,40</sup> Of note, there have been no bearing surface failures using XLPE in this or any prior resurfacing study. The favorable results in this study can be attributed to careful patient selection, careful bone-conserving surgical technique, and the use of high-quality XLPE and components with high osseointegration potential.

## Author's Note

The author certifies that he has institutional approval for this study and the investigation was conducted in conformity with ethical principles of research and that informed consent was obtained.

The work was performed at the Wyss Hip and Pelvis Center, Seattle, WA, USA.

This work is a revision of a previous submission that was rejected by the Bone Joint Journal.

## Declaration of conflicting interest

JWP certifies that he has no commercial associations (consultancies, stock ownership, equity interest, patent/licensing arrangements, etc.) that might pose a conflict of interest with this article.

## Funding

This research received no specific grant from any funding agency in the public, commercial, or not-for-profit sectors.

## References

- Amstutz HC, Le Duff MJ, Campbell PA, et al. Clinical and radiographic results of metal-on-metal hip resurfacing with a minimum ten-year follow-up. *J Bone Joint Surg* 2010; 92A: 2663–2671.
- Beaulé PE and Antoniadou J. Patient selection and surgical technique for surface arthroplasty of the hip. *Orthop Clin North Am* 2005; 36: 177–185.
- Malviya A, Lobaz S and Holland J. Mechanism of failure eleven years following a Buechel Pappas hip resurfacing. *Acta Orthop Belg* 2007; 73: 791–794.
- Pritchett JW. Success rates of the TARA hip. *Am J Orthop* 1998; 27: 658.
- Yue EJ, Cabanela ME, Duffy GP, et al. Hip resurfacing arthroplasty: risk factors for failure over 25 years. *Clin Orthop Relat Res* 2009; 467: 992–999.
- Kendal AR, Prieto-Alhambra D, Arden NK, et al. Mortality rates at 10 years after metal-on-metal hip resurfacing compared with total hip replacement in England: retrospective cohort analysis of hospital episode statistics. *BMJ* 2013; 347.
- McMinn DJ, Snell KI, Daniel J, et al. Mortality and implant revision rates of hip arthroplasty in patients with osteoarthritis: registry based cohort study. *BMJ* 2012; 344.
- Barrack RL, Ruh EL, Berend ME, et al. Do young, active participants perceive advantages after surface replacement compared to cementless total hip arthroplasty? *Clin Orthop Relat Res* 2013; 471: 3803–3813.
- Matharu GS, McBryde CW, Pynsent WB, et al. The outcome of the Birmingham Hip Resurfacing in patients aged < 50 years up to 14 years post-operatively. *Bone Joint J* 2013; 95-B: 1172–1177.
- Schmalzreid TP, Silva M, de la Rosa MA, et al. Optimizing patient selection and outcomes with total hip resurfacing. *Clin Orthop Relat Res* 2005; 441: 200–204.
- Costa ML, Achten J, Parsons NR, et al. Young Adult Hip Arthroplasty Team. Total hip arthroplasty versus resurfacing in the treatment of patients with arthritis of the hip joint; single centre parallel group, assessor blinded, randomised controlled trial. *BMJ* 2012; 344: e2147.
- Dunbar MJ, Prasad V, Weerts B, et al. Metal-on-metal hip resurfacing replacement: the routine use is not justified. *Bone Joint J* 2014; 96B: 17–21.
- Freeman MA, Cameron HU and Brown GC. Cemented double cup arthroplasty of the hip: a 5 year experience with the ICLH prosthesis. *Clin Orthop Relat Res* 1978; 134: 45–52.
- Pritchett JW. Curved-stem hip resurfacing: minimum 20-year followup. *Clin Orthop Relat Res* 2008; 466: 1177–1185.
- Coulter G, Young DA, Dalziel RE, et al. Birmingham hip resurfacing at a mean of ten years: results from an independent centre. *J Bone Joint Surg* 2012; 94B: 315–321.
- McBryde CW, Theivendran K, Thomas AM, et al. The influence of head size and sex on the outcome of Birmingham hip resurfacing. *J Bone Joint Surg* 2010; 92A: 105–112.
- Daniel J, Ziaee H, Salama A, et al. The effect of the diameter of metal-on-metal bearings on systemic exposure to cobalt and chromium. *J Bone Joint Surg* 2006; 88B: 444–448.
- de Steiger RN, Miller LN, Prosser GH, et al. Poor outcome of revised resurfacing hip arthroplasty. *Acta Orthop* 2010; 81: 72–76.
- Kurtz S, Austin M, Azzam K, et al. Mechanical properties, oxidation, and clinical performance of retrieved highly crosslinked Crossfire liners after intermediate-term implantation. *J Arthroplasty* 2010; 25: 614–623.
- Kurtz SM, Gawel HA and Patel JD. History and systemic review of wear and osteolysis outcomes for first-generation highly crosslinked polyethylene. *Clin Orthop Relat Res* 2011; 469: 2262–2277.
- Pritchett JW. Very large diameter polymer acetabular liners show promising wear simulator results. *J Long Term Eff Med Implants* 2016; 26: 311–319.
- Kelly NH, Rajadhyaksha AD, Wright TM, et al. High stress conditions do not increase wear of thin highly crosslinked UHMWPE. *Clin Orthop Relat Res* 2010; 468: 418–423.
- Lachiewicz PF, Heckman DS, Soileau ES, et al. Femoral head size and wear of highly cross-linked polyethylene at 5 to 8 years. *Clin Orthop Relat Res* 2009; 467: 3290–3296.
- Martell JM, Verner JJ and Incavo SJ. Clinical performance of highly cross-linked polyethylene at two years in total hip arthroplasty: a randomized prospective trial. *J Arthroplasty* 2003; 18(7 Suppl. 1): 55–59.
- Shen F, Lu Z and McKellop HA. Wear versus thickness and other features of 5-Mrad crosslinked UHMWPE acetabular liners. *Clin Orthop Relat Res* 2011; 469: 395–404.
- Amstutz HC, Takamura KM, Ebrahimzadeh E, et al. Highly cross-linked polyethylene in hip resurfacing arthroplasty: long-term follow-up. *Hip Int* 2015; 25: 39–43.
- Pritchett JW. Heat generated by hip resurfacing prostheses: in vivo pilot study. *J Long-Term Effects Med Implants* 2011; 21: 55–62.
- Pritchett JW. Conservative total articular replacement arthroplasty: minimum 20-year follow-up. In: McMinn DJW (ed.) *Modern hip resurfacing*. London: Springer, 2009, pp.408–414.
- Pritchett JW. Hip resurfacing using highly cross-linked polyethylene: prospective study results at 8.5 years. *J Arthroplasty* 2016; 31: 2203–2208.
- Brooker AF, Bowerman JW, Robinson RA, et al. Ectopic ossification following total hip replacement. Incidence and a method of classification. *J Bone Joint Surg* 1973; 55A: 1629–1632.
- Harris WH. Traumatic arthritis of the hip after dislocation and acetabular fractures: treatment by mold arthroplasty. An end-result study using a new method of result evaluation. *J Bone Joint Surg* 1969; 51A: 737–755.

32. Ware JE, Kosinski M and Keller SD. *SF-12: How to score the SF-12 physical and mental health summary scales*. 3rd ed. Lincoln, RI: Quality Metric Incorporated, 1998.
33. Johnson C. A new method for roentgenographic examination of the upper end of the femur. *J Bone Joint Surg* 1932; 14A: 859–866.
34. DeLee JG and Charnley J. Radiological demarcation of cemented sockets in total hip replacement. *Clin Orthop Relat Res* 1976; 121: 20–32.
35. Mall NA, Nunley RM, Zhy JJ, et al. The incidence of acetabular osteolysis in young participants with conventional versus highly crosslinked polyethylene. *Clin Orthop Relat Res* 2011; 469: 372–381.
36. Le Duff MJ, Wang CT, Wisk LE, et al. Benefits of thin-shelled acetabular components for metal-on-metal hip resurfacing arthroplasty. *J Orthop Res* 2010; 28: 1665–1670.
37. Kurtz SM, MacDonald DW, Mont MA, et al. Retrieval analysis of sequentially annealed highly crosslinked polyethylene used in total hip arthroplasty. *Clin Orthop Relat Res* 2015; 473: 962–971.
38. Buechel FF. Evolving technologies: new answers or new problems? Hip resurfacing revisited. *Orthopedics* 1996; 19: 753–756.
39. Buechel FF Sr and Pappas MJ. A metal/ultrahigh-molecular-weight polyethylene cementless surface replacement. *Semin Arthroplasty* 2011; 22: 66–74.
40. Haddad FS, Konan S and Tahmassebi J. A prospective comparative study of cementless total hip arthroplasty and hip resurfacing in patients under the age of 55 years: a ten-year follow-up. *Bone Joint J* 2015; 97B: 617–622.
41. Dumbleton JH, Manley MT and Edidin AA. A literature review of the association between wear rate and osteolysis in total hip arthroplasty. *J Arthroplasty* 2002; 17: 649–661.
42. Loughhead JM, Starks I, Chesney D, et al. Removal of acetabular bone in resurfacing arthroplasty of the hip. A comparison with hybrid total hip arthroplasty. *J Bone Joint Surg* 2006; 88B: 31–34.
43. Vendittoli PA, Lavigne M, Girard J, et al. A randomised study comparing resection of acetabular bone at resurfacing and total hip replacement. *J Bone Joint Surg* 2006; 88B: 997–1002.